Hallux Valgus Correction: An Alternative Approach

Noman A. Siddiqui, DPM, MHA, AACFAS,[1] Guido LaPorta, DPM, MS, FACFAS,[2] and Jossie Abraham, DPM, AACFAS[3]

[1]International Center for Limb Lengthening, Rubin Institute for Advanced Orthopedics, Sinai Hospital, Baltimore, Maryland, USA [2]Geisinger Community Medical Center, Scranton, Pennsylvania, USA

[3]Orthopaedic Specialty Group, P.C, Fairfield, Connecticut, USA

The Food and Drug Administration has approved all devices and pharmaceuticals for the uses described. Disclosures: The authors do not have any conflicts of interest to report.

Statement of Purpose

- Hallux valgus is a common forefoot condition traditionally treated surgically with open dissection techniques.
- Many open methods have been described in the literature to correct the mal-alignment of the first metatarsophalangeal joint that results from this condition.
- The authors utilized an alternative method to correct hallux valgus deformity using a percutaneous approach.

Literature Review

- Bösch et al.[1] reported the long-term follow-up of 114 feet that underwent minimally invasive bunion correction. Patient satisfaction was 81% with 95% of patients reporting no pain.
- Magnan et al.[2] reported results of 118 patients undergoing a similar correction with patient satisfaction at 91% after 3 years.
- Chiang et al.[3] reported a retrospective radiographic review of 62 feet comparing the outcomes of the Ludloff osteotomy with the minimally invasive distal first metatarsal osteotomy for hallux valgus. They found an invasive approach had equivalent clinical results when compared to the Ludloff osteotomy. However, long-term follow-up showed that minimally invasive correction was shown to have fewer recurrences.
- Kadakia et al.[4] reported the results of 13 patients. The study was abandoned due to the high complication rate, thus the procedure was not recommended.

Case Study

Procedure

- Insert 2-mm wire percutaneously from the distal phalanx to the head of first metatarsal (Fig. 1).
- Make a medial 0.5-cm incision, and perform a minimal soft-tissue dissection of the first metatarsal.
- Place a 1.8-mm wire into first metatarsal neck as an axis guide (Figs. 2A and 2B).
- Perform a multiple drill hole osteotomy with a 1.8-mm wire (Fig. 2C).
- Complete the osteotomy with a mini-micro sagittal saw or an osteotome (Fig. 3).
- Translate the capital fragment and maintain reduction with 2-mm wire (Fig. 4).
- Confirm reduction and wire placement under fluoroscopy in AP and lateral views (Fig. 5).
- Complete closure and apply dressings.
- Illustration (Fig. 6A) and radiograph (Fig. 6B) show bone after consolidation is achieved.

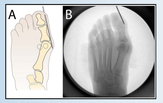

Figure 1. A and B, Insert pin from distal tip of great toe subperiosteally to metatarsal head.

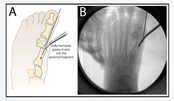

Figure 4. A and B, Kelly hemostat guides K-wire into the proximal fragment.



Figure 2. A and B, Place 1.8-mm axis guide wire at metatarsal neck. C, Use additional wires to create multiple drill holes.

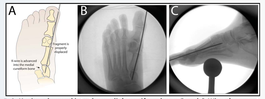

Figure 5. A, K-wire advanced into the medial cuneiform bone. B and C, Wire placement and reduction are confirmed on AP (B) and lateral (C) view fluoroscopic images.

Figure 3. Use osteotome (A and B) or mini micro sagittal blade (C) to complete osteotomy.

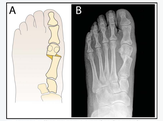

Figure 6. Illustration (A) and radiograph (B) show bone after consolidation is achieved.

Methods

- Medical records were retrospectively reviewed of 50 patients who underwent treatment between 2009 and 2014 at three institutions.
- Correction was assessed by measuring hallux valgus and intermetatarsal angles preoperatively and at most recent follow-up.
- A Wilcoxon Signed Rank Test was utilized for statistical analysis. A p-value of less than 0.05 was used to determine significance.

Figure 7. A, Preoperative radiograph shows mild hallux valgus. B, Postoperative radiograph obtained at 2.5-year follow-up. Reduction has been maintained. Note the remodeling of the medial shelf.

Figure 8. A, Photograph obtained before treatment shows hallux valgus deformity. This is the same patient that is shown in Figures 1 through 6. B and C, Photographs obtained 6 months after surgery. The hyper-pigmented skin on the lateral view photograph denotes the site of the incision. D, Excellent range of motion was maintained at the first metatarsophalangeal joint.

Results

- Fifty patients (fifty feet) were included in the study (Figs. 7 and 8).
- Both the average hallux valgus and intermetatarsal angle significantly decreased by 1-year follow-up:
  - Average hallux valgus angle: 30.4° to 9.6° ($p<0.001$)
  - Average intermetatarsal angle: 14.2° to 6.3° ($p<0.001$)
- No nonunions were observed.
- Four adverse events occurred and fully resolved:
  - Pin-site infection: 2 cases
  - First metatarsal medial shelf irritation: 2 cases

Analysis and Discussion

- Percutaneous surgery utilizing minimal dissection is a viable method to correct hallux valgus deformity.
- The procedure has been validated in the literature to have equivalent healing and correction of deformity when compared with traditional open surgery.
- Patients may develop pin-site infection or medial shelf irritation.
  - Pin-site infection can be managed effectively with oral antibiotics.
  - Medial shelf irritation may require a return to the operating room for resection of bony prominence.
- This alternative approach has a learning curve; however, the procedure can be effectively performed if surgeons do not deviate from the surgical technique.

References

1. Bösch P, Wanke S, Legenstein R. Hallux valgus correction by the method of Bösch: a new technique with a seven-to-ten-year follow-up. Foot Ankle Clin 2000;5(3):485–98, v-vi. Review.

2. Magnan B, Pezzè L, Rossi N, Bartolozzi P. Percutaneous distal metatarsal osteotomy for correction of hallux valgus. J Bone Joint Surg Am 2005;87(6):1191–9.

3. Chiang CC, Lin CF, Tzeng YH, Huang CK, Chen WM, Liu CL. Distal linear osteotomy compared to oblique diaphyseal osteotomy in moderate to severe hallux valgus. Foot Ankle Int 2012;33(6):479–86.

4. Kadakia AR, Smerek JP, Myerson MS. Radiographic results after percutaneous distal metatarsal osteotomy for correction of hallux valgus deformity. Foot Ankle Int 2007;28(3):355–60.

© 2015 Sinai Hospital of Baltimore